



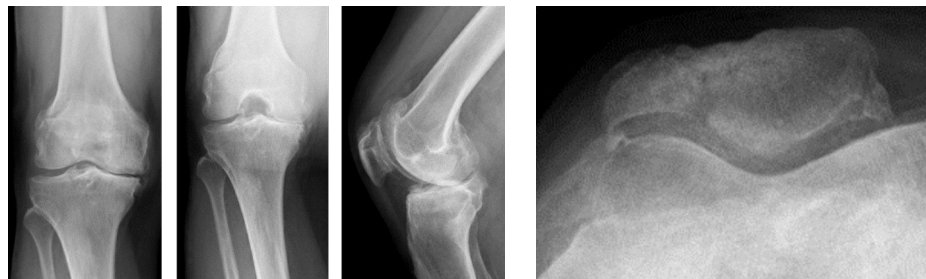# Mako Total Knee SmartRobotics™



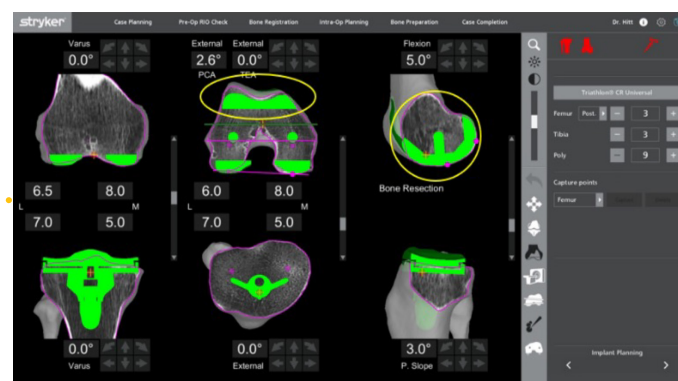
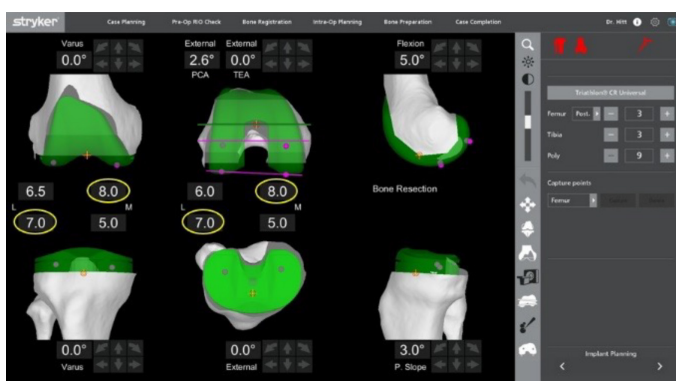
## ► Case review with Kirby Hitt, M.D.

### Patient history / Pre-op x-rays

- 69-year-old female
- BMI 33



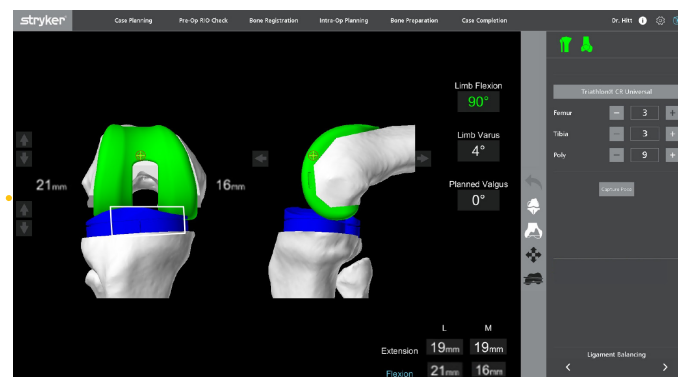
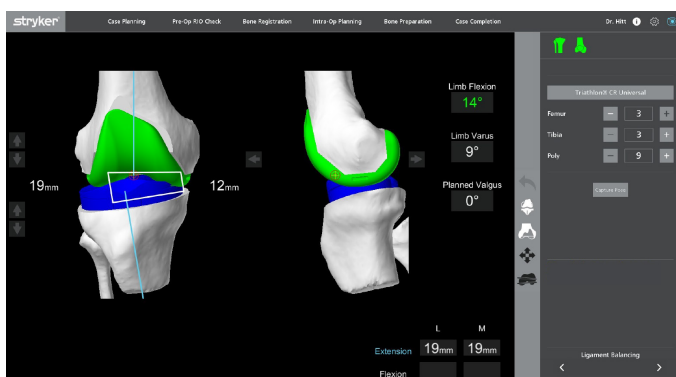
### 3D CT-based pre-planning



The 3D CT-based pre-plan demonstrates that the operative knee is in varus. The plan is set to the default planning parameters, and the planned component sizes are 3 femur and 3 tibia with the Triathlon Knee System.

In CT view, the surgeon assesses the concentricity of the medial femoral condyle in the sagittal plane and trochlea congruency in the transverse plane.

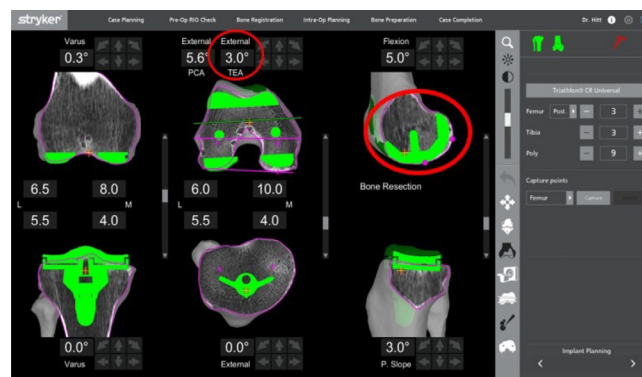
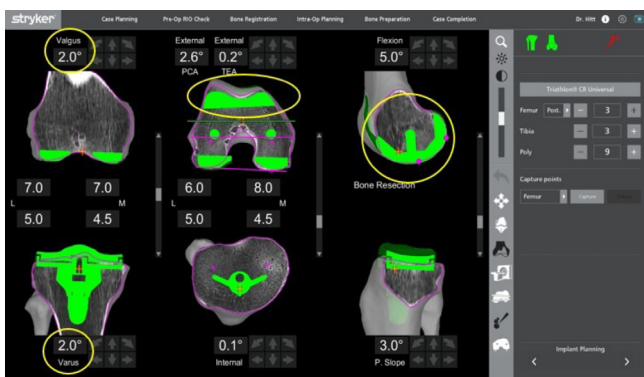
### Ligament laxity assessment



Bone registration is complete, and the plan is verified within 1 millimeter of the CT scan. In extension, the native deformity demonstrates a 14° flexion contracture and a 9° varus deformity. The surgeon applies a valgus stress to tension the MCL, resulting in symmetric laxities, and captures these values in the laxity table.

In flexion, the surgeon assesses both the medial and lateral compartments together by applying tension to the joint. This results in asymmetric laxities, and these values are captured in the laxity table.

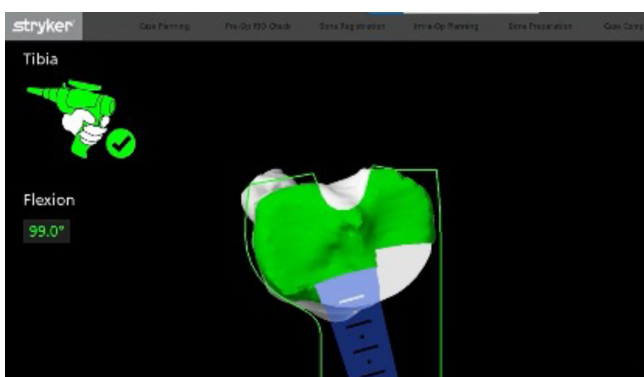
## Implant planning



To balance the asymmetric flexion gaps, the surgeon pivots laterally on the tibia to add 2° of varus, pivots centrally on the femur to add 2° of valgus, and proximalizes the tibia. These adjustments balance the knee in flexion, while maintaining medial femoral stability in the sagittal plane, trochlea congruity and posterior condylar offset.

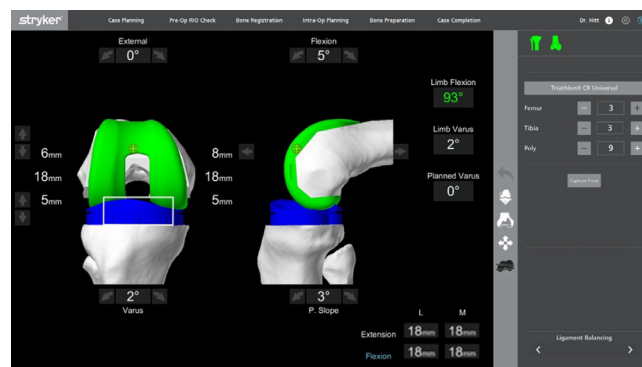
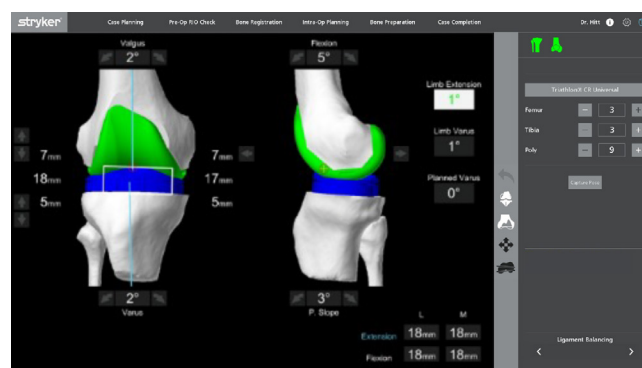
An alternative option to balance the knee is to pivot centrally and externally rotate the femur. This method was not chosen because the sagittal femoral position is altered and the trochlea is overstuffing.

## AccuStop™ haptic technology



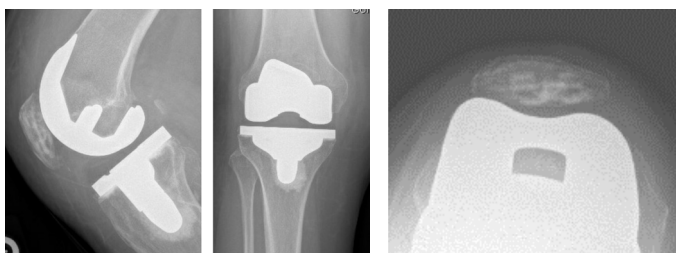
The surgeon completes bone preparation using AccuStop™ haptic technology. The saw is constrained in the virtual boundary that is established by the surgeon's patient-specific plan, as seen in step 5.

## Trialing



Trialing assessment demonstrates that the limb is capable of reaching full extension, the varus deformity was corrected from 9° to 1° varus and the knee is symmetrically balanced in both extension and flexion.

## Post-op x-rays



## Learn more about Mako Total Knee SmartRobotics™



Dr. Hitt is a paid consultant of Stryker Orthopaedics. The opinions expressed by Dr. Hitt are those of Dr. Hitt and not necessarily those of Stryker. Individual experiences may vary. A surgeon must always rely on his or her own professional clinical judgment when deciding whether to use a particular product when treating a particular patient. Stryker does not dispense medical advice and recommends that surgeons be trained in the use of any particular product before using it in surgery.

The information presented is intended to demonstrate the breadth of Stryker's product offerings. A surgeon must always refer to the package insert, product label and/or instructions for use before using any of Stryker's products. Products may not be available in all markets because product availability is subject to the regulatory and/or medical practices in individual markets. Please contact your sales representative if you have questions about the availability of products in your area.

Stryker Corporation or its divisions or other corporate affiliated entities own, use or have applied for the following trademarks or service marks: AccuStop, Mako, SmartRobotics, Stryker, Triathlon. All other trademarks are trademarks of their respective owners or holders.

MAKTKA-COM-55\_34413  
Copyright © 2022 Stryker