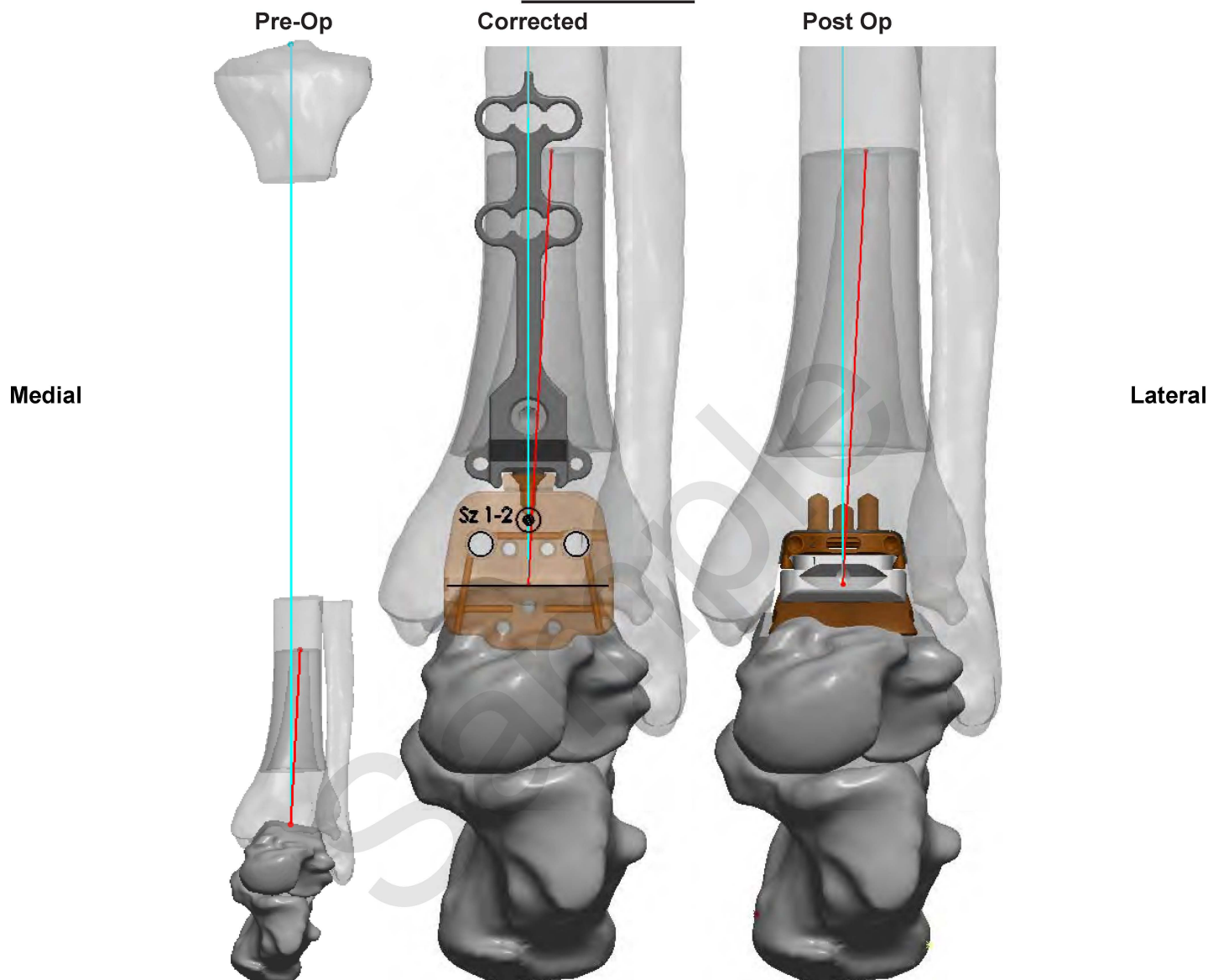


CASE##### - Surgeon: Dr. Training Demo
 Sample Report - Left - Surgery: DD-MM-YYYY

INFINITY Size 2 Tibia & Size 1 INFINITY Talus

Anterior Views



— Tibia Mechanical Axis
 — Tibia Anatomic axis

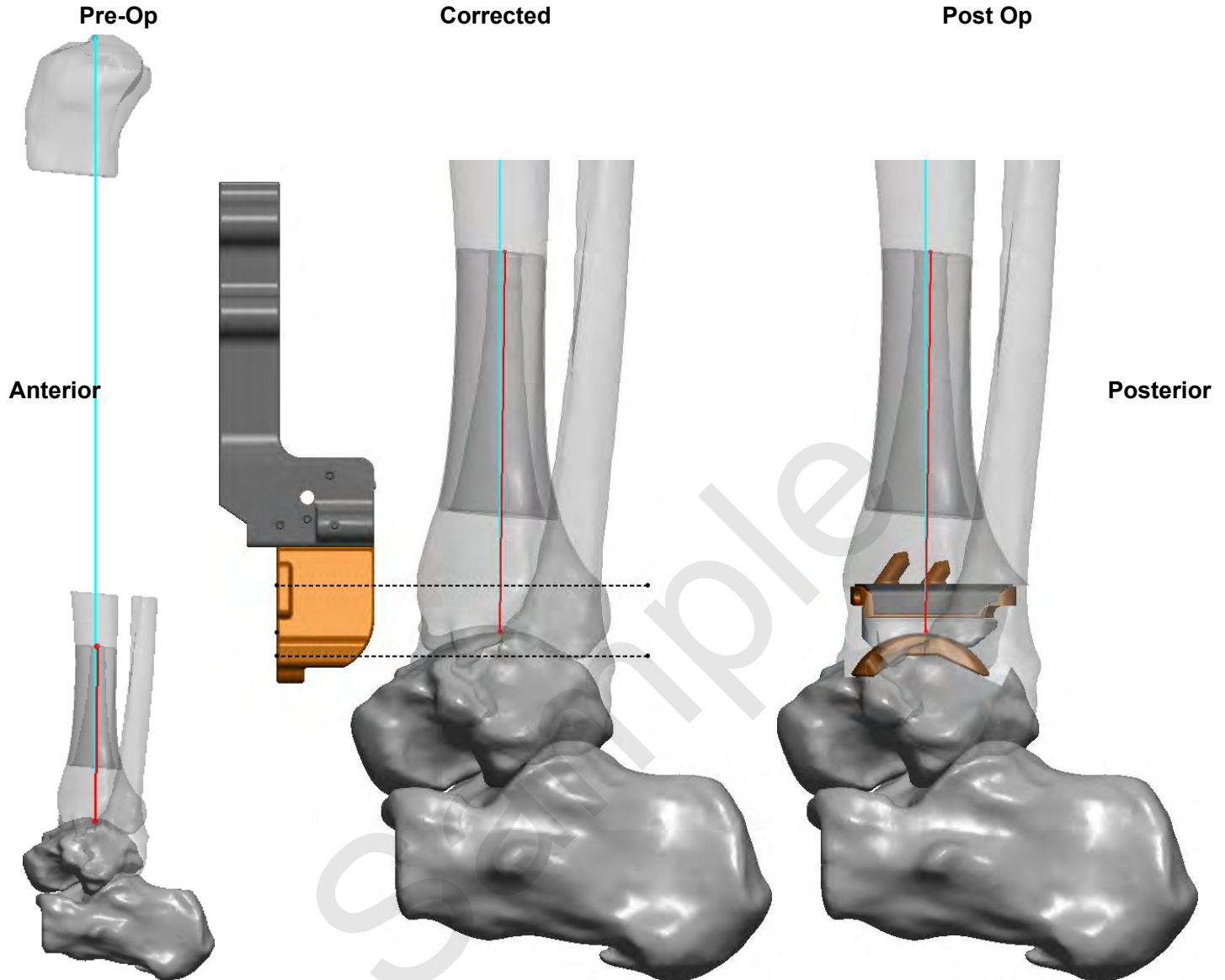
Axis Angles
Anatomic vs. Mechanical
 Coronal = 3.1°

Tibia Implant Alignment

- Coronal Plane: **Mechanical (long) Axis**
- Sagittal Plane: **Mechanical (long) Axis**

Medial/Lateral placement is set:

- to **Match medial gutter corner**
- to **ensure there is bone coverage on lateral implant.**
- Medial malleolus at implant corner: **12.4 mm.**

stryker**Prophecy®** | Surgical Planning
Preoperative Navigation System**INFINITY Size 2 Tibia and Size 1 INFINITY Talus****Sagittal Views from Lateral Side****Implant Information**

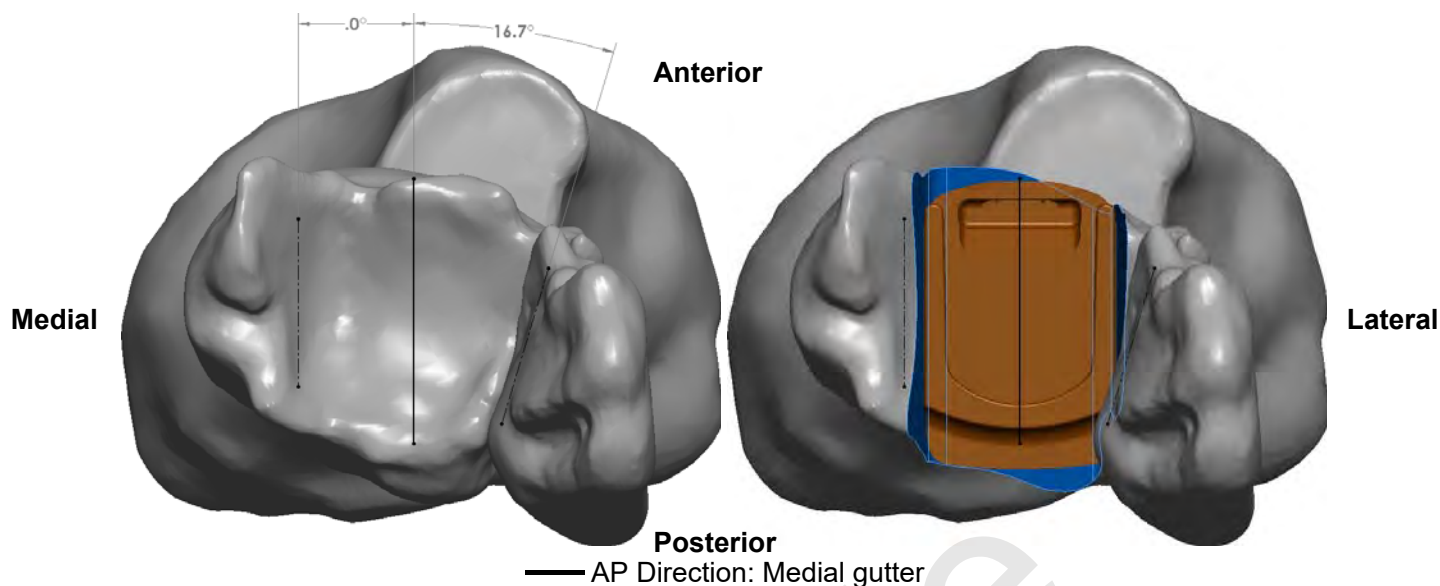
Tibial tray: Sz 2
(33650002)
Tibial insert: Sz 1
(33651106)

Talar dome: Sz 1 INFINITY
(33630021)

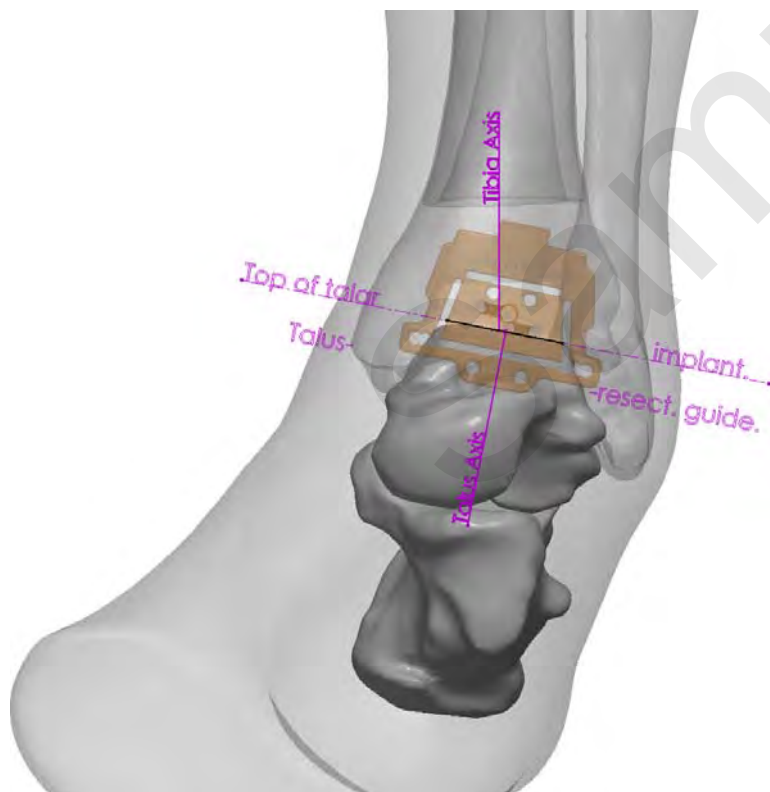
PROPHECY Part Number:
PROPINFF

Axis Angles
Anatomic vs. Mechanical
Sagittal = 0.8°

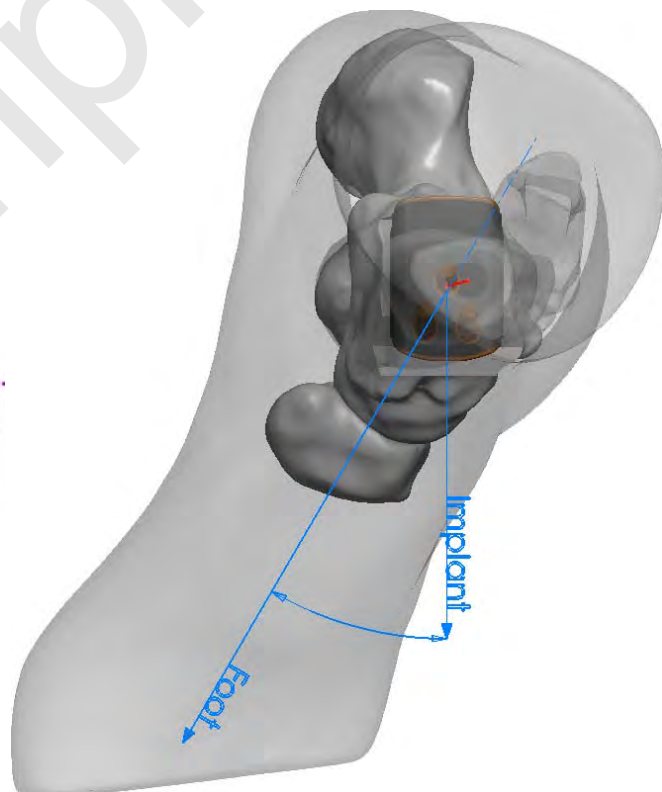
INFINITY Size 2 Tibia and Size 1 INFINITY Talus Tibia Rotation Distal Views



- Tibia gutter angle: 16.7°.
- A-P Tibia implant placement: ~1.9 mm from the anterior extent of the tibia.
- Posterior uncovered tibia resection: 2.9 mm.

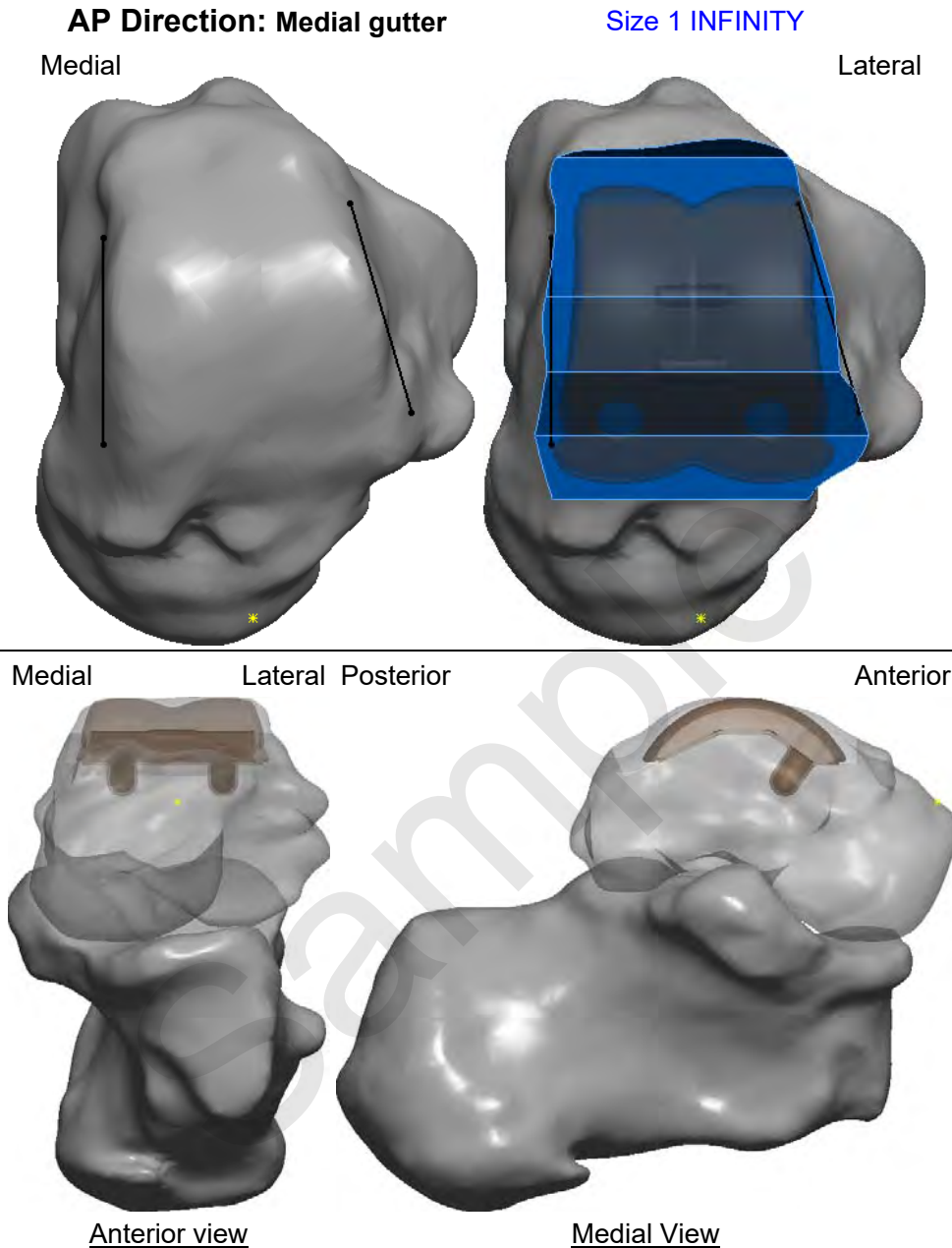


Talus resection guide relative to the talar bone and the planned tibia alignment axis. The resections will result in a correction of 11.1° from varus. Ligament balancing may be necessary to achieve balance



The tibia internal/external orientation is 30.2° external to the approximate foot orientation.

INFINITY Size 2 Tibia and Size 1 INFINITY Talus Talus Rotation Top Views



Notes:

- Talus resection angle in Coronal Plane: **parallel to the natural talar dome**.
- Size **1 INFINITY** talus implant is selected to maximize bone coverage while minimizing implant overhang.
- Talar Gutter angle: 16.3° . Talus anterior direction: **Medial gutter**.
- The resection depth is set to **0 mm** more than the thickness of the talar implant.
- The distal flat of the talar implant is **6.2 mm** proximal to the yellow talar neck point shown above.

Summary

Tibial Alignment Method

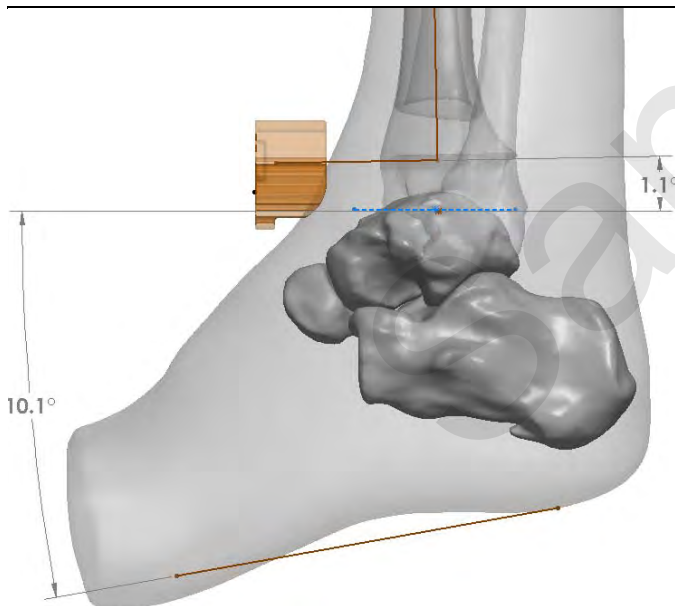
- Tibia Implant Alignment in Coronal Plane: Mechanical (long) Axis.
- Tibia Implant Alignment in Sagittal Plane: Mechanical (long) Axis.
- Anterior direction is set by the Medial gutter.
- Medial/lateral implant placement:
 - Match medial gutter corner.
 - The cuts on the medial malleolus and fibula are minimized.
 - Upsize for AP tibial coverage.
- Anterior/Posterior implant placement: ~1.9 mm from the anterior extent of the tibia

Talar Alignment Method

- Talus implant flexion is set to: approximately parallel to the ground from the sagittal weight bearing x-ray. See appendix ii.
- Talus implant is selected to maximize bone coverage while minimizing implant overhang.
- Anterior direction is set by Medial gutter.
- Resection depth: 0 mm more than the thickness of the talar implant.

PROPHECY Engineering Comments

- The external rotation of the tibia implant is aligned to the anatomy of the ankle gutters. This orientation results in an implant that appears to be rotated approximately 30.2° external to the foot position during the CT scan. This is a limited measurement due to the laxity of the foot during the scan and the patient's plantar-flexion positioning during the CT scan (see bottom of page 5). The actual rotational value in the OR may be different if the foot is repositioned.

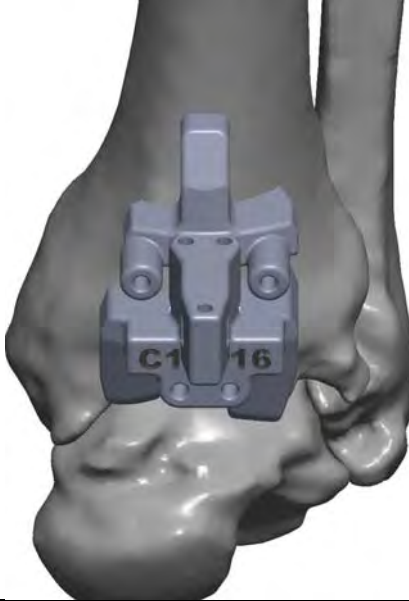

Sagittal view of pre-op talus showing:

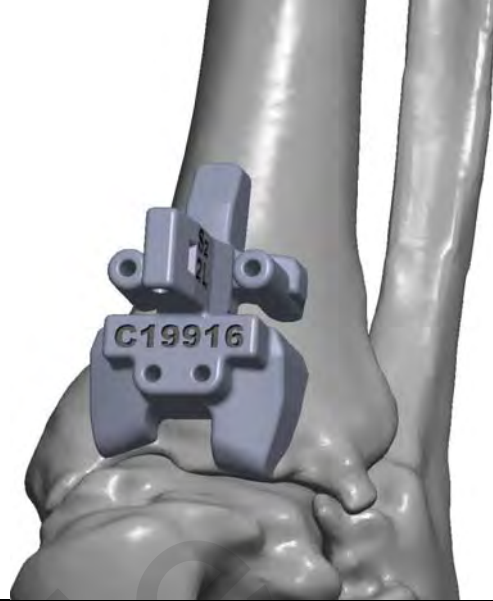- Talus resection vs. tibia resection.
- Talus resection vs. bottom of foot line.

Tibial Alignment Guide

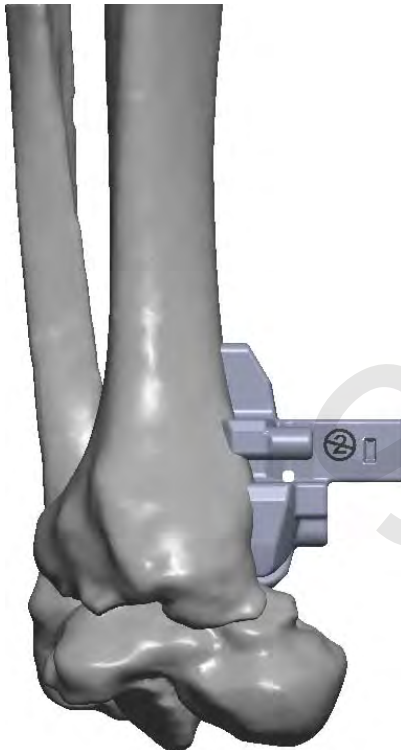
Superior view



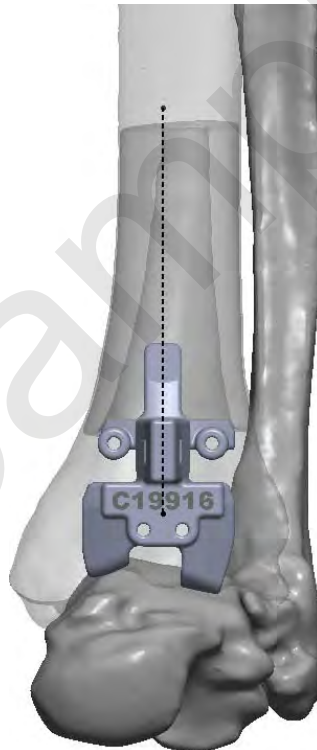
Inferior Oblique View



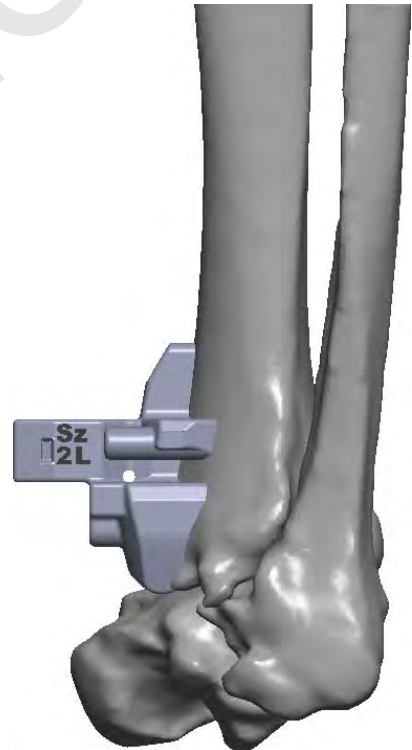Medial view



Anterior View



Lateral View

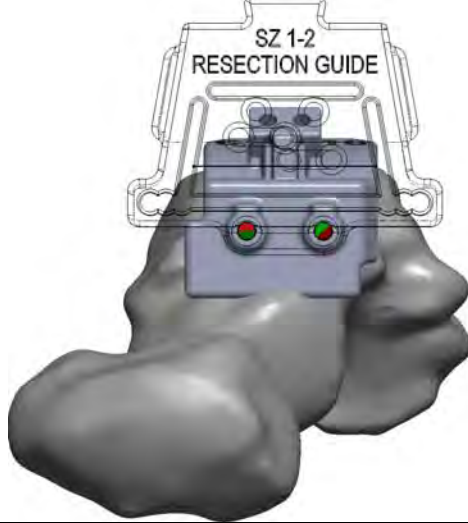


Tibia Guide Comments:


- The tibia guide as designed is in close proximity to the patient's talar bone, therefore the talus may need to be plantarflexed prior to placing the tibia alignment guide. Ensure a bump is placed under the distal tibia.

Talar Alignment Guide

Anterior view, with the navicular and resection guide



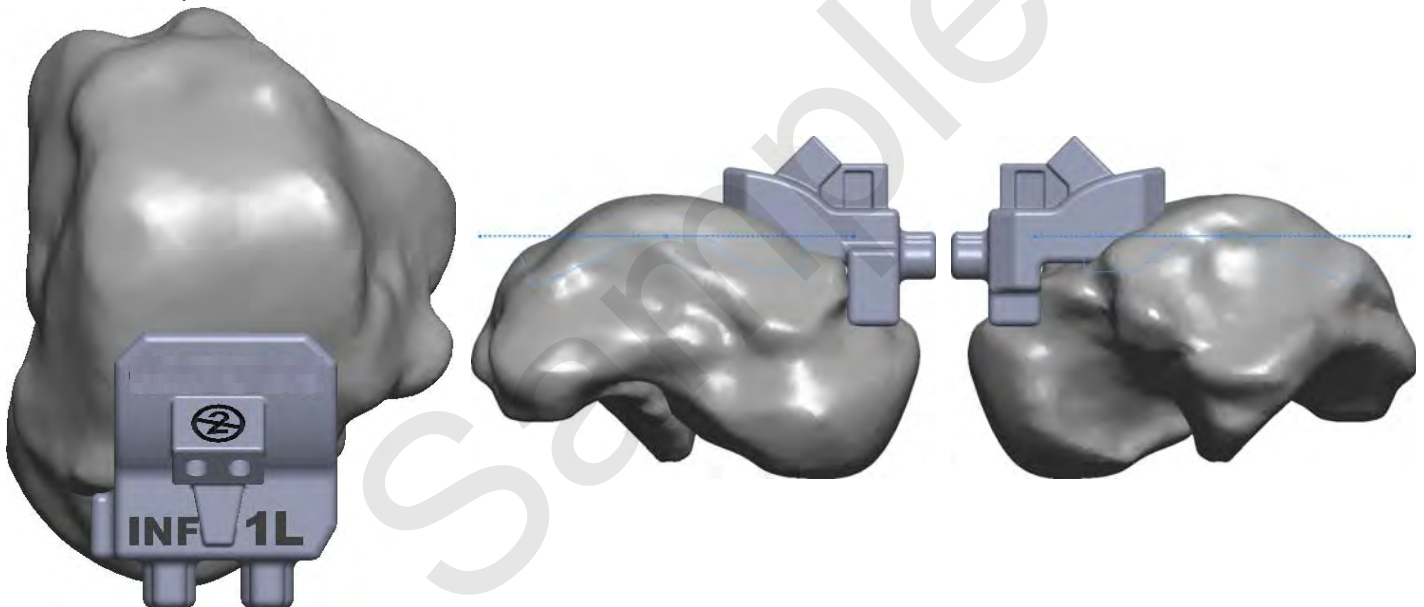
Superior Oblique View



Superior view

Medial View

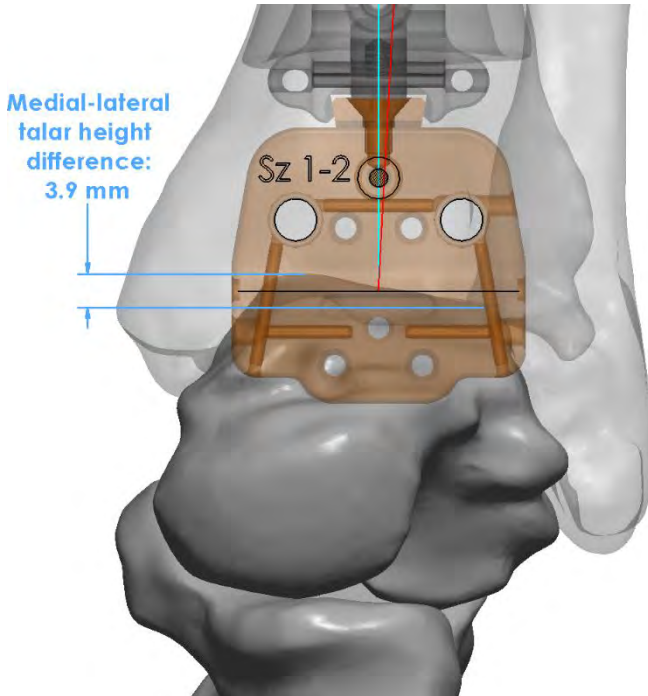
Lateral View



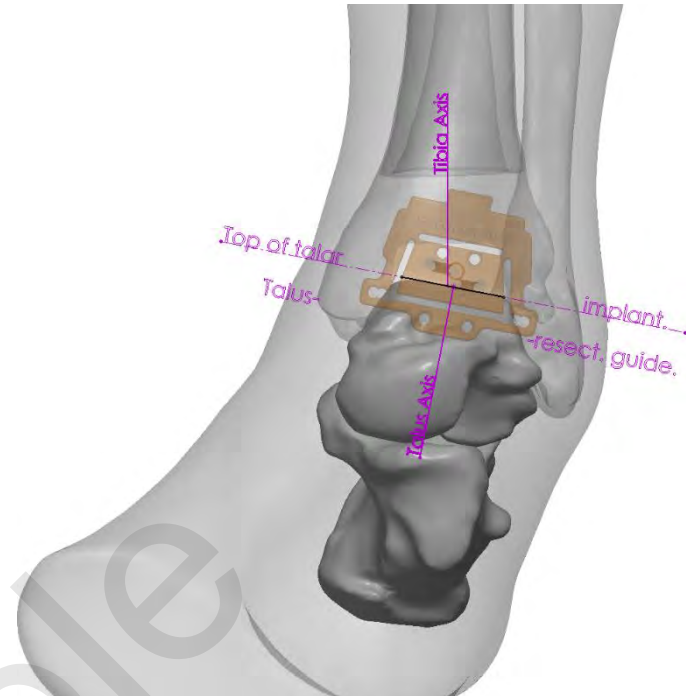
Talus Guide Comments:

- Talar guide designed for use with: **size 1-2 INF-INF resection guide.**

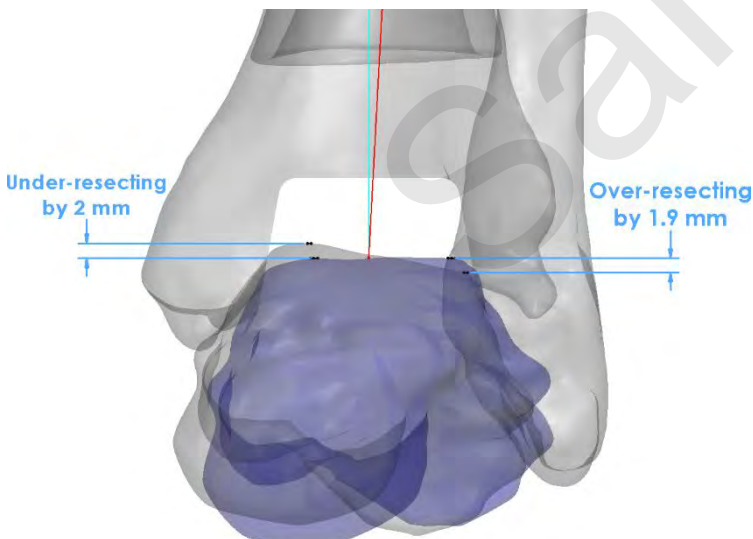
CASE##### - APPENDIX: Talus Resection Angle and Tibia Resection Height



Pre-op medial-lateral talar height difference:
3.9 mm



Talus resection guide relative to the talar bone and the planned tibia alignment axis. The resections will result in a correction of 11.1° from varus.

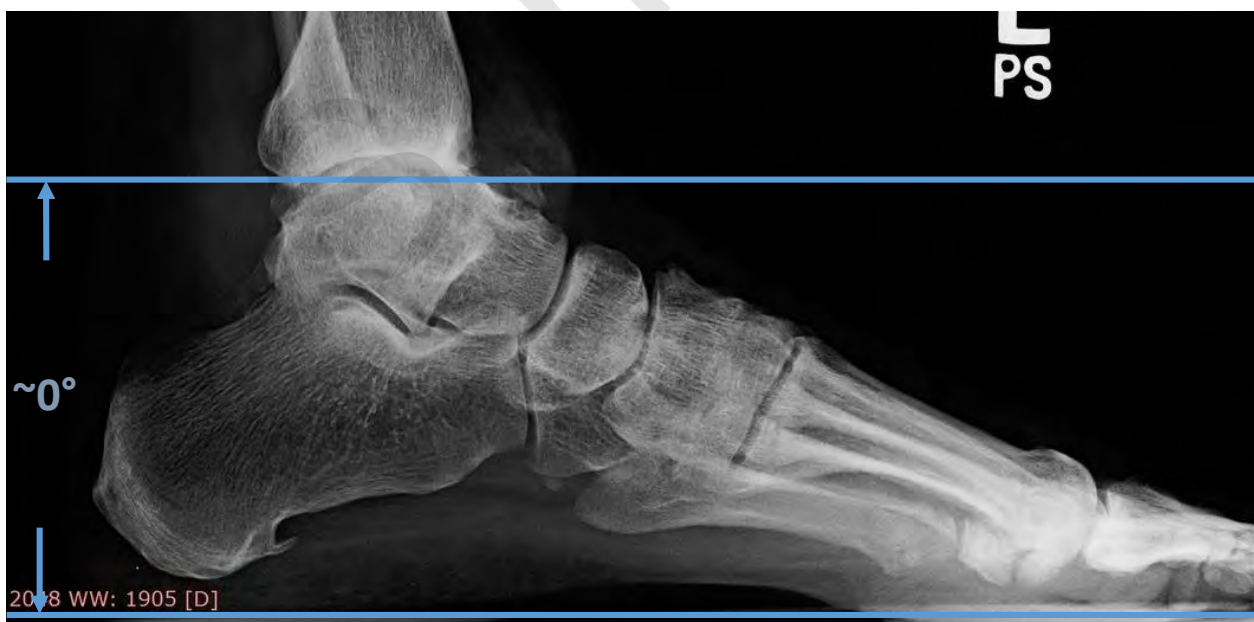
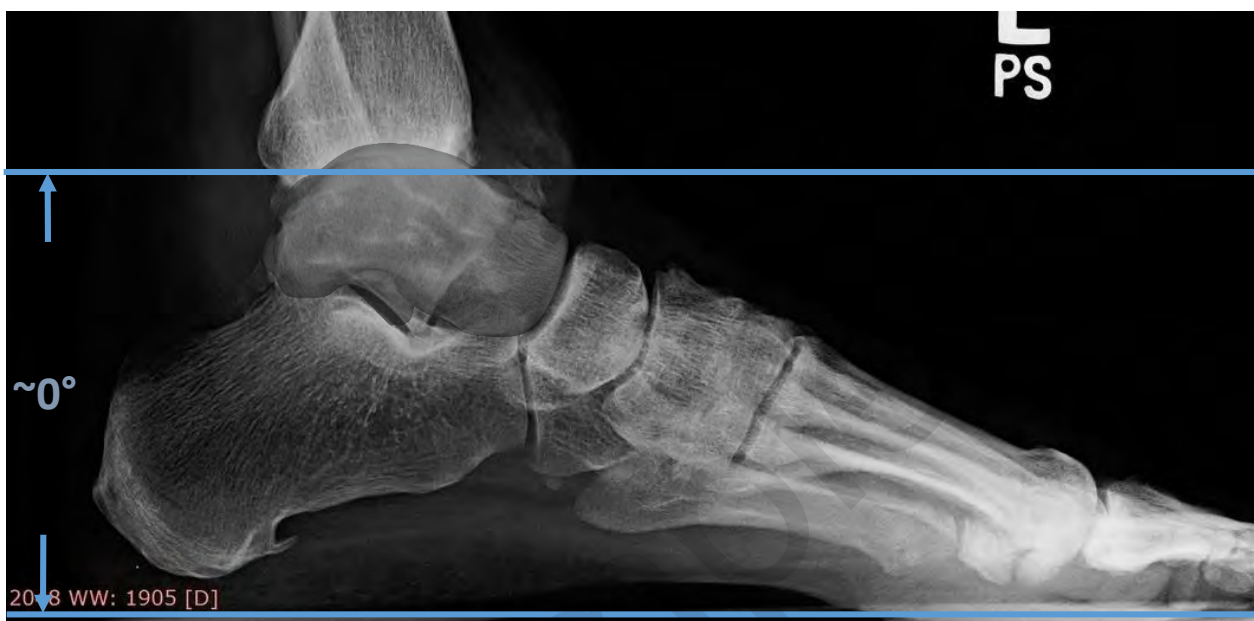
The swing of the talus & overall resection height (relative to standard implant height). The "corrected" talus is highlighted.

The tibia resection height has been set as shown by the "under-resecting" value to restore some height of the joint. This distal translation of the talus means resecting less bone than the full height of the implant on one side to reduce the likelihood of requiring the thickest polyethylene. Given the current tibia resection height and the thinnest polyethylene, it is expected that the high side of the talus will be forced distally by the "under-resecting" measurement, and the opposite side may have residual laxity in the amount of the "over-resecting" value. Ligament balancing may be necessary to achieve correction.

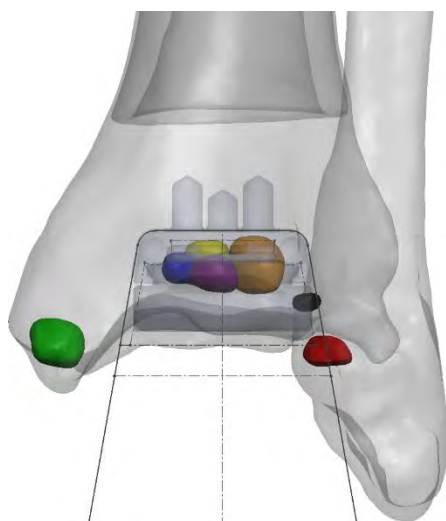
CASE##### - APPENDIX: Talar resection angle when weight-bearing

- The following images show the approximate registration of the 3D model of the talus from the CT scan to the sagittal weight bearing x-ray provided.
- Therefore, the planned talar resection angle has $\sim 0^\circ$ of slope relative to the ground from the sagittal weight bearing x-ray.

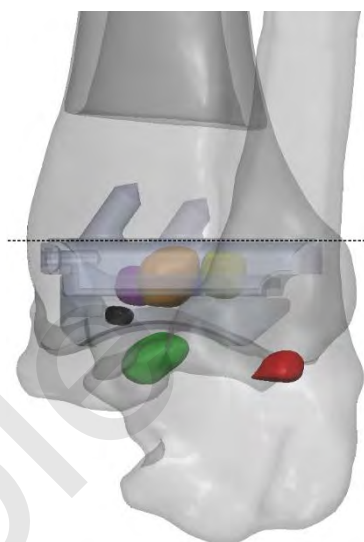


CASE##### - APPENDIX: Bone Void

Any bone voids are shown below relative to the implant(s) and resection plane(s). Please refer to the patient's CT scan for more details.



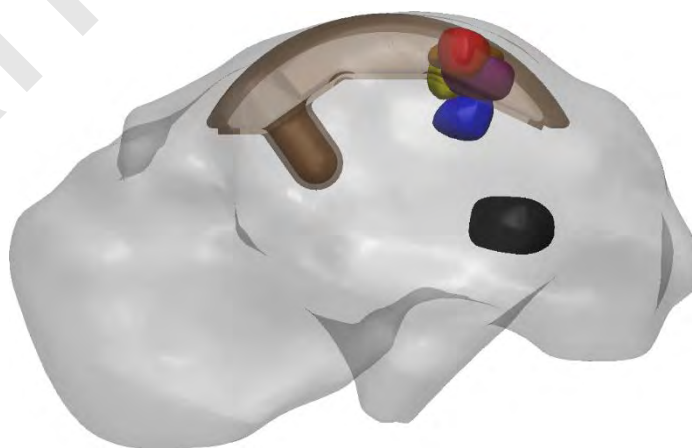Anterior view of tibia and fibula with implant.



Lateral view of tibia and fibula with implant.



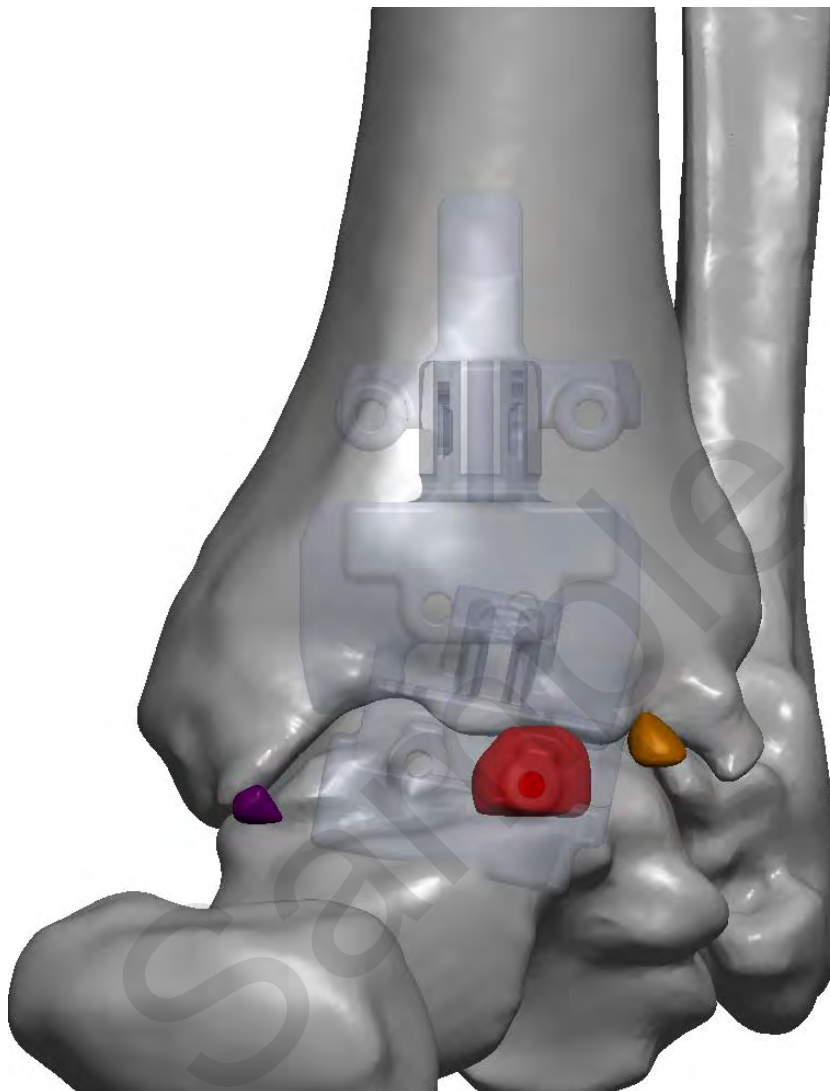
Anterior view of talus with implant.



Sagittal view of talus with implant.

CASE##### - APPENDIX: Osteophyte

Any loose body osteophytes shown below that interfere with the alignment guides will need to be removed prior to placing the guides.

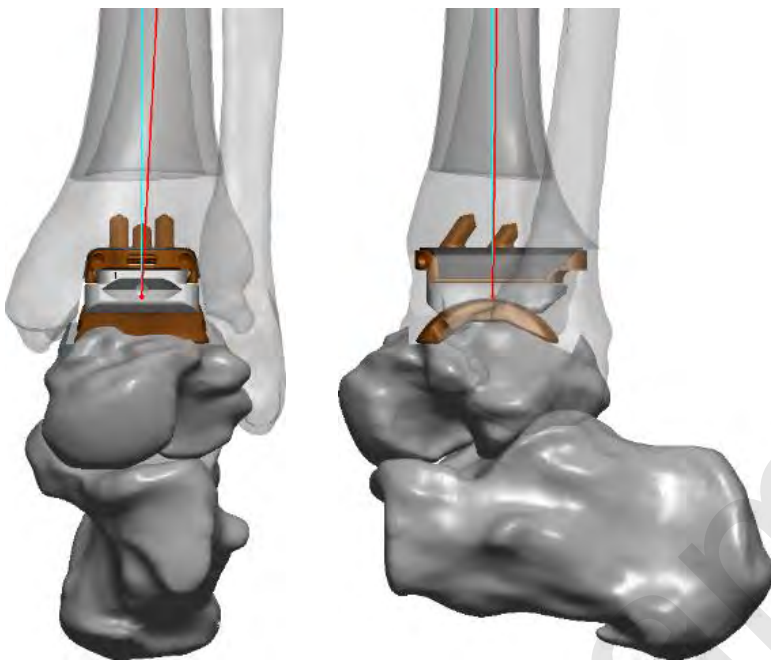


Alignment guides at tibia-talus joint line relative to any osteophyte(s). Anterior view

CASE##### - APPENDIX: Alternative size implants

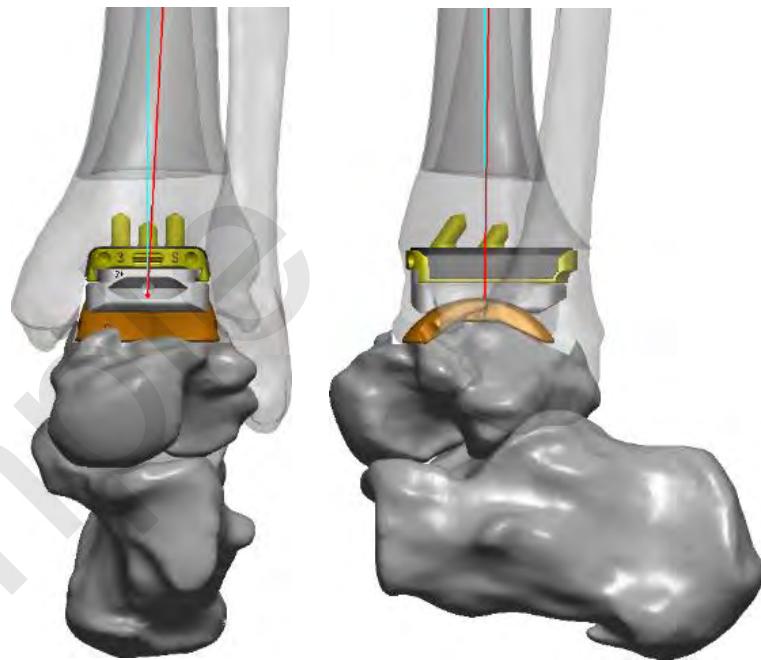
- This case is somewhat between sizes.
- The above report utilizes a size 2 tibia which spares medial malleolus, and a size 1 talus which reduces talar overhang.
- An alternative size 3 Std tibia tray which achieves wider M-L tibia coverage, and size 2 talus which provides fuller talar coverage are shown below.
- The report does not need to be rejected in order to use the alternative size. The size choice can be made intraoperatively so long as the appropriate poly insert is used.

Current Size

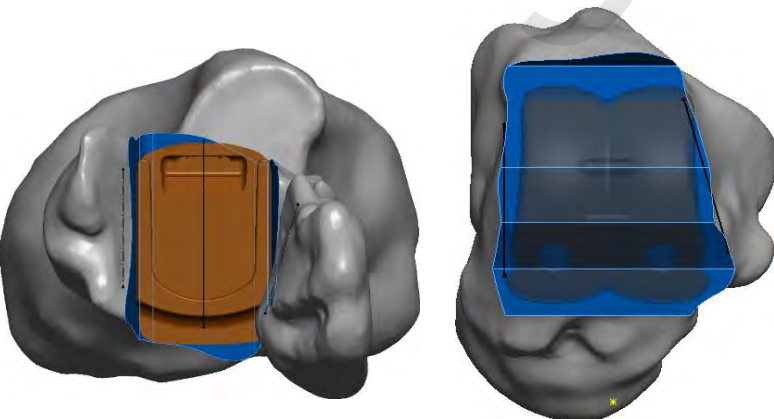


Anterior and lateral images for the current size 2 tibia, 1 talus implants. Medial mal thickness remaining ~12.4 mm.

Alternative Size

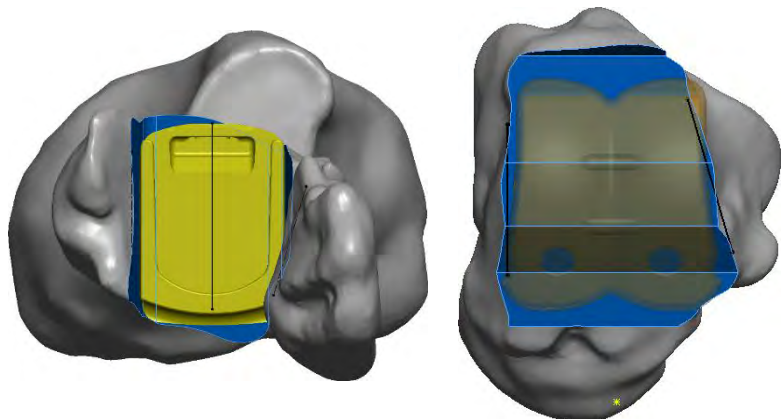


Anterior and lateral images for the alternative size 3 Std tibia, 2 talus implants. Medial mal thickness remaining ~11.5 mm.



Size 2 tibia. Distal view.
2.9 mm of posterior
uncovered bone

Size 1 talus. Proximal
View



Size 3 Std tibia. Distal
view. 2.9 mm of posterior
uncovered bone

Size 2 talus. Proximal
View

Prophecy® Footprint™

stryker

CASE##### - APPENDIX: Prophecy Footprint

SUMMARY OF ANCILLARY PROCEDURES TO CONSIDER:

The following is a summary of considerations provided for the pre-surgical planning of the ankle and surrounding anatomy to support the total ankle implant. These considerations are proposed with reference to the radiographic images and inputs. Further details are provided in subsequent pages.

COMMONLY CONSIDERED

- Deltoid ligament release **AND/OR** Lateral Ligament reconstruction
- Lateral Gutter Debridement
- First Metatarsal Dorsiflexion Osteotomy (closing wedge) or First Tarsometatarsal Joint Dorsiflexion Fusion

OCCASIONALLY CONSIDERED

- Posterior Tibial Tendon Release or Lengthening
- Peroneus Longus to Peroneus Brevis Tendon Transfer

Prophecy® Footprint™

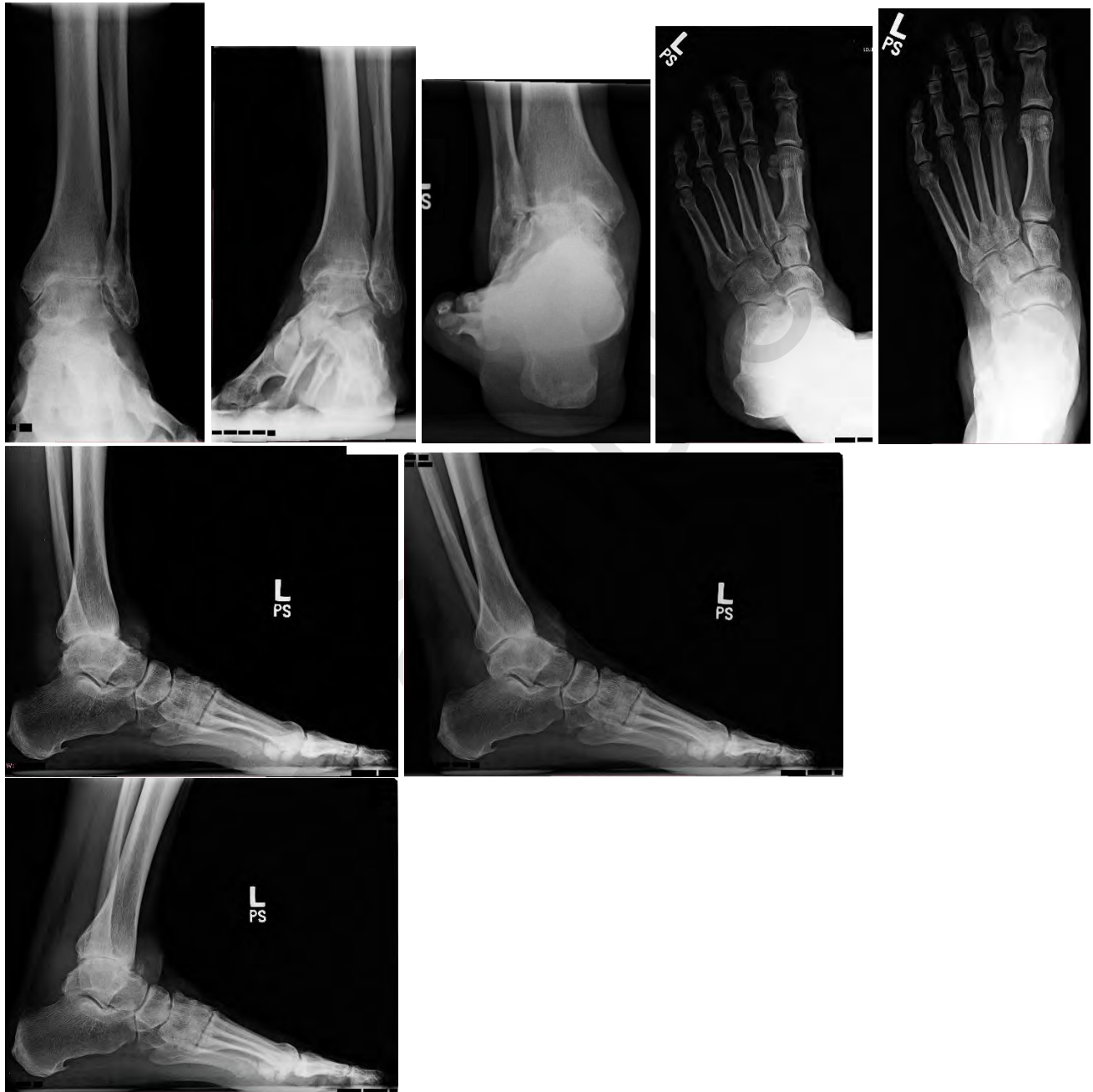stryker

CASE##### - APPENDIX: Prophecy Footprint

INPUTS SUPPLIED (X-RAYS, IMAGES, CLINICAL NOTES):

The following patient image thumbnails and clinical notes were supplied for evaluation for Prophecy® Footprint™. These images are reproduced below for reference only and may be lower resolution than the original images.

Images:



Prophecy® Footprint™

stryker

CASE##### - APPENDIX: Prophecy Footprint

ANCILLARY PROCEDURES COMMONLY CONSIDERED:

- Deltoid ligament release AND/OR Lateral Ligament reconstruction:
 - Deltoid ligament release - If the medial soft tissues at the ankle are preventing reducing the tibio-talar joint to varus, consider releasing the deltoid ligaments either by "pie crusting" or peeling the deltoid off of the tibia. If restoration to neutral is not achieved, consider other medial structure releases such as a posterior tibial tendon lengthening, long flexor tendon lengthening, and/or talar-navicular release.
- AND/OR
 - Lateral Ligament reconstruction - The deformity at the ankle and residual deformity of the foot might suggest insufficiency of the lateral ligament complex in this patient and a need for additional stabilization. It is reasonable to perform a lateral ligament reconstruction through a separate lateral incision, after the ankle is implanted. Options for this reconstruction might include anatomic reconstruction by advancing the lateral ligament complex onto the fibula (Broström), anatomic reconstruction by advancing the lateral ligaments onto the talus and calcaneus (reverse Broström), using peroneal tendons and/or allograft, or a non-anatomic reconstruction (Chrisman-Snook/Evans).
- Lateral Gutter Debridement - As observed from the pre-operative patient anatomy, there appears to be bone overgrowth laterally and/or distally that could prevent reduction of the talus to neutral and cause secondary gutter impingement. Consider decompressing and debriding the lateral gutter. When performed, it may be expected that bone be removed from both the medial fibula and the lateral talus and even calcaneus if impingement is present there. A separate lateral incision may be considered, given the depth of the lateral gutter and difficulty accessing the inferior fibula through an anterior approach.
- First Metatarsal Dorsiflexion Osteotomy (closing wedge) or first tarsometatarsal joint dorsiflexion fusion - If the patient has a residual cavus foot deformity following reconstruction of the Varus ankle and the malrotated midfoot, the 1st ray is often plantarflexed. A dorsiflexion osteotomy at the base of the first metatarsus and/or a first tarsometatarsal (TMT) fusion may be performed. One might defer to the fusion depending on the apex of the deformity, magnitude of deformity, and arthritis of the first TMT joint.

Prophecy® Footprint™

stryker

CASE##### - APPENDIX: Prophecy Footprint

ANCILLARY PROCEDURES OCCASIONALLY CONSIDERED:

- Posterior Tibial Tendon Release or Lengthening - If adduction deformity is significant (or rigid), or if the varus hindfoot deformity is rigid, a posterior tibial tendon release or lengthening may be appropriate. Generally, this is determined intra-operatively when correction of adduction or varus becomes difficult due to rigid contracture. It may be performed in addition to a capsulotomy of the TN joint. The tendon may be lengthened via Z-lengthening or coronal plane lengthening or released from its insertion in severe cases. In addition, the talonavicular capsulotomy should try to avoid the spring ligament so that talonavicular congruence is maintained.
- Peroneus Longus to Peroneus Brevis Tendon Transfer - In patients with cavovarus foot deformity, overpull of the peroneus longus tendon may exacerbate plantarflexion of the first ray. To combat this, consider transferring the peroneus longus tendon to the peroneus brevis tendon in a side-to-side tendodesis at the level of the peroneal tubercle.

Sample